

## Splenic Torsion in Pregnancy: A Case Report

<sup>1</sup>Oluwrotimi Akinola, <sup>1</sup>Adetokunbo Fabamwo, <sup>1</sup>Kabiru Rabi,

<sup>1</sup>Adetokunbo Tayo, <sup>2</sup>Folusho Omodele and <sup>3</sup>Rachael Akinola

<sup>1</sup>Department of Obstetrics and Gynecology,

<sup>2</sup>Department of Surgery, <sup>3</sup>Department of Radiology,

College of Medicine, Lagos State University, Teaching Hospital, Ikeja Lagos, Nigeria

---

**Abstract:** A 29-years-old primigravid female presented at the emergency, unit of the teaching hospital with an acute abdomen at 28th week pregnancy in shock. An emergency abdominal ultrasound scan excluded an extrauterine pregnancy but, there was massive free fluid in the peritoneal cavity and an enlarged spleen. Exploratory laparotomy confirmed a torqued spleen with bleeding from a tiny tear in the splenic vein into the peritoneal cavity and an enlarged spleen. Splenectomy was performed. Patient however, went into labour on the 3rd postoperative day and was delivered of a female stillborn.

**Key words:** Splenic torsion, hemorrhage, spasmolytics, antiemetics, laparotomy, ultrasound

---

### INTRODUCTION

Splenic torsion is an exceedingly rare complication in pregnancy. Its coexistence with pregnancy creates a diagnostic dilemma because, intrinsic pregnancy complications might mask its symptoms. Most cases of splenic pathology in pregnancy reported in literature were of rupture (Huang *et al.*, 2006), but when apparently precipitated by a previously undiagnosed torsion, throws a challenge for differential diagnosis and has been rarely reported as a cause of massive intra abdominal hemorrhage in pregnancy (Seah and Tan, 1964).

We present, a case of a primigravid patient, who presented late with an acute abdomen in shock and had the correct diagnosis made only at exploratory laparotomy.

### CASE REPORT

Mrs. Oo, a 29 years old, Para 0+0 quantity surveyor, presented to the emergency department of the hospital on the 2nd of July 2007 at a gestational age of 29 weeks. Presenting complaints were difficulty with breathing, vomiting, weakness, dizziness, fainting spells, severe abdominal pain and progressive abdominal swelling. Pregnancy had been uneventful except for occasional complaints of epigastric pain that was relieved by antacid. She claimed to have been well until, 3 days earlier when she felt epigastric pain, which she felt was due to peptic ulcer disease and so she took antacids. She however, felt

worse and was taken to a private hospital where, she was found to be in pain and was pale. She was managed with intravenous fluids, spasmolytics and antiemetics.

Her condition however, continued to worsen with pallor increasing, while the vital signs deteriorated. An ultrasound scan done confirmed a viable intrauterine pregnancy with free fluid in the peritoneal cavity. The patient was transfused with 1 unit of blood and referred to the teaching hospital. Past medical history revealed a 2 years history of recurrent dyspepsia and epigastric pain, which was relieved by taking antacids. There was no preceding history of abdominal trauma.

On examination, the patient was acutely ill looking, severely pale, anicteric, extremities were cold and clammy and her respiratory rate was 64 min<sup>-1</sup>. Her pulse rate was 124 min, while the blood pressure was 80/40 mmHg. The abdomen was grossly distended, uniformly tender with rebound tenderness all over. It was difficult to define the enlarged uterus because of tenderness. There was no bleeding per vaginam, the cervix was posterior with marked excitation tenderness, it was not effaced and the os was closed. A provisional diagnosis of acute abdomen secondary to ruptured extra uterine pregnancy, ruptured uterus or spontaneous splenic rupture was made. She was immediately commenced on resuscitation with intravenous fluids and blood transfusion. An emergency abdominal ultrasound scan of the abdomen revealed a viable intrauterine pregnancy of 28 weeks gestation, with a large heterogeneous irregularly outlined spleen that has an ill-defined margin. There was massive free fluid in the

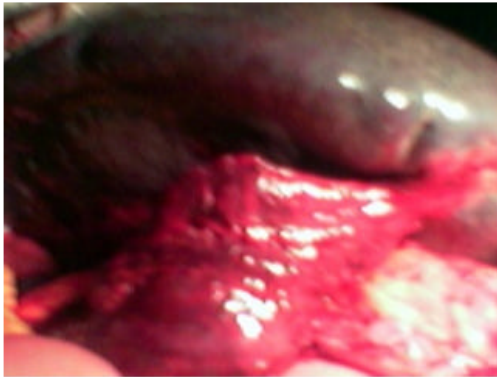

Fig. 1: Oedematous splenic pedicle

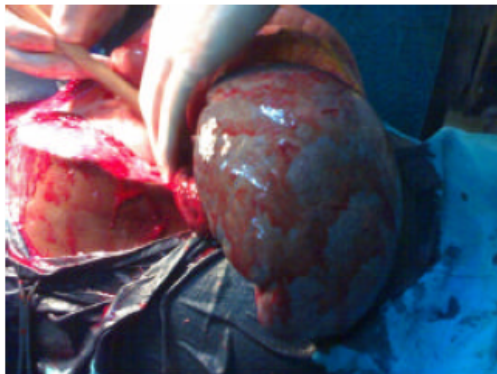


Fig. 2: Enlarged spleen on its twisted pedicle

peritoneal cavity though all the other organs were normal. At exploratory laparotomy about 2 L hemoperitoneum, a normal gravid uterus was shown. The spleen was found to be grossly enlarged in the left hypochondrium above the uterine horn, it was grayish black in colour with punctuate hemorrhagic areas. Its pedicle was oedematous, measured about 12 cm (Fig. 1). There was a 2 and a half times clockwise rotation of the spleen on the pedicle (Fig. 2). The splenic vein was engorged with a tiny tear from which, it was bleeding. The pedicle was untwisted and splenectomy was performed. She was transfused with 4 units of blood and made a good recovery. However, she went into labour and expelled an 860 g female stillbirth on the 3rd post operative day.

## DISCUSSION

Splenic torsion is a rare cause of acute or recurrent abdominal pain in pregnancy or the puerperium (Huang *et al.*, 2006; Denehy *et al.*, 1988; Gilman and Thomas, 2003). It is a complication of the wandering

spleen (Seah and Tan, 1964) a rare condition characterized by increased splenic mobility due to the absence or laxity of its suspensory ligaments that may present as acute abdomen when it is twisted on its pedicle (Alimoglu *et al.*, 2004). It has been reported in conditions such as abdominal trauma, splenomegaly, non specific abdominal muscle laxity and laxity resulting from the hormonal effects of pregnancy (Swischuk *et al.*, 1993). Splenic torsion leading to splenic vein rupture is rarer still and is associated with high mortality (Seah and Tan, 1964; Safeoleas and Moulakakis, 2006).

It has been suggested that the softening effect of pregnancy hormones on ligaments, the abdominal musculature, diminished peritoneal cavity volume as a result of the gravid uterus and a maximal third trimester increase in whole blood volume might be the predisposing factors in pregnancy (Huang *et al.*, 2006; Parvaiz, 2004).

This patient had been taking medication for about 2 years for an undiagnosed peptic ulcer disease and early symptoms such as epigastric pain, dyspepsia, vomiting during the antenatal period were easily ascribed to peptic ulcer disease.

Symptoms of splenic torsion vary depending on the degree of torsion, hence while, mild torsion might manifest with chronic abdominal pain resulting from congestion, moderate torsion might manifest with severe intermittent abdominal pain related to intermittent rotation and derotation. Huang *et al.* (2006) and severe and acute torsion present with symptoms suggestive of an intra abdominal catastrophe (Seah and Tan, 1964; Swischuk *et al.*, 1993; Parvaiz *et al.*, 2004; Robinson, 1998).

The acute abdomen with signs of hemorrhagic shock on presentation made ruptured uterus, a complications of abdominal pregnancy with placental detachment the most probable diagnosis in the environment. Spontaneous splenic rupture, which though rare, has been encountered in the practice was also considered. The parlous state of the patient limited the amount of time and investigations possible but, the ultrasound scan excluded the strongest differential diagnosis.

In view of limited diagnostic tools in the environment, it is suggested that non specific dyspepsia complaints by pregnant women, recurrent abdominal pain be taken more seriously and investigated and when indicated, early recourse to exploratory laparotomy during, which other systems other than reproductive are sought should be considered. This is even more important when, patients with hemoglobinopathies, who are prone to abdominal vaso occlusive and sequestration crises in pregnancy have been excluded.

## CONCLUSION

Therefore, splenic torsion, though rare should be considered a differential diagnosis in pregnant patients, who present with symptoms of shock and acute abdomen.

## REFERENCES

- Alimoglu, O., M. Sahin and M. Akleg, 2004. Torsion of a wandering spleen presenting with acute abdomen: A case report. *Acta Chir. Belg.*, 104: 221-223. PMID: 15154585. <http://www.belsurg.org/showartikel.asp?id=549>.
- Denehy, T., E.W. Mcgrath and J.L. Breen, 1988. Splenic torsion and rupture in pregnancy. *Obstet. Gynecol. Surv.*, 43: 123-131. PMID: 3285257. <http://medind.nic.in/jaq/t07/i6/jaq07i6p545.pdf>.
- Gilman, R.S. and R.L. Thomas, 2003. Wandering spleen presenting as acute pancreatitis in pregnancy. *Obstet. Gynecol.*, 101: 1100-1102. PMID: 12738115. [http://www.ncbi.nlm.nih.gov/pubmed?term=Gilman+Rachel\[au\]](http://www.ncbi.nlm.nih.gov/pubmed?term=Gilman+Rachel[au]).
- Huang, Y.H., C.Y. Hsu, Y.F. Chang and C.P. Chen, 2006. Postcesarean Splenic Torsion. *Taiwan J. Obstet. Gynecol.*, 45: 257-259. PMID: 17175476. <http://www.ncbi.nlm.nih.gov/sites/entrez>.
- Parvaiz, A., S. Chandran, A. Karim, K. Kumar, P. Jeffrey and N.R. Lagattolla, 2004. Torted and ruptured wandering spleen presenting as a surgical emergency in pregnancy. *Scientific World J.*, 4: 1035-1037. PMID: 15632981. <http://www.ncbi.nlm.nih.gov/pubmed/15632981>.
- Robinson, A.P., 1988. Wandering Spleen: Case report and review. *Mt. Sinai J. Med.*, 55: 428-434. PMID: 3063960. <http://www.ncbi.nlm.nih.gov/sites/entrez>.
- Safeoleas, M.C. and K.G. Moulakakis, 2006. A rare cause of intra-abdominal hemorrhage: Spontaneous rupture of the Splenic vein. *Acta. Chir. Belg.*, 106: 237-239. PMID: 16761488. <http://www.belsurg.org/showartikel.asp?id=877>.
- Seah, C.S. and N.C. Tan, 1964. Torsion of Spleen With Spontaneous Rupture of Splenic Vein Presenting as a case of accidental hemorrhage. *Br. Med. J.*, 1: 1028. PMID: 14108477. [http://www.ncbi.nlm.nih.gov/pubmed/14108477?ordinalpos=2&itool=EntrezSystem2.PEntrez.Pubmed.Pubmed\\_ResultsPanel.Pubmed](http://www.ncbi.nlm.nih.gov/pubmed/14108477?ordinalpos=2&itool=EntrezSystem2.PEntrez.Pubmed.Pubmed_ResultsPanel.Pubmed).
- Swischuk, L.E., J.B. Williams and S.D. John, 1993. Torsion of a wandering spleen: The whorled appearance of the splenic pedicle on CT. *Pediatr. Radiol.*, 23: 476-477. PMID: 8255657. <http://www.ncbi.nlm.nih.gov/sites/entrez>.