

## Efficiency Assessment of Iranian Honey on Healing of Linea Alba Following Exploratory Laparotomy in Animal Model

<sup>1</sup>Farnood Shokouhi Sabet Jalali, <sup>1</sup>Siamak Saifzadeh, <sup>2</sup>Amir Abbas Farshid,

<sup>3</sup>Hossien Tajik, <sup>4</sup>Reza Bagheri and <sup>5</sup>Rahim Mohammadi

<sup>1</sup>Department of Clinical Sciences, <sup>2</sup>Department of Pathobiology,

<sup>3</sup>Department of Food Hygiene, <sup>4</sup>Graduate student in Veterinary Medicine,

<sup>5</sup>Postgraduate student in Veterinary Surgery, College of Veterinary Medicine, Urmia University, Urmia, Iran

**Abstract:** The aim of this study was to examine the effectiveness of topical administration of Iranian honey in acceleration of healing of linea alba and prevention or reduction of post-surgical peritoneal adhesions in dog. The study was conducted with 20 adult dogs with mean weight of  $20 \pm 2.42$  Kg. The animals were selected randomly and divided into two equal groups. Laparotomy was performed routinely on all animals through a caudal midline abdominal incision of 10 cm length. Control group received saline treatment and in experiment group the lesions were treated with honey. The abdominal incision was then closed with continuous pattern of 0 polyglactine 910 (vicryl) suture. Three weeks after laparotomy, the dogs were sacrificed and the adhesions were graded according to their degree of severity based on Evans's scoring system. Overall, 60% (n = 6) of the control animals and 20% (n = 2) of the experiment animals presented with moderate (grade 2) and severe (grade 3) adhesions. In the experiment group, there were 8 (80%) dogs with grade-0 or grade-1 adhesions but in the control group there were 4 (40%) dogs with the same grades of adhesions. The difference between two groups was shown to be significant ( $p < 0.05$ ). Histological analysis revealed that honey did not induce a specific inflammatory reaction and caused a fibrotic response compared with the untreated group. Inflammatory reactions were seen as disseminated foci of inflammatory cells in control group. Based on the results of this study, it was concluded that honey appears to be a useful treatment for acceleration healing of lineae alba and had high effectiveness in reducing post-operative adhesions.

**Key words:** Honey, healing, lineae alba, laparotomy, dog

### INTRODUCTION

Laparotomy is of high importance both in medical and veterinary medicine. The primary goal of this operation is to explore abdominal cavity in order to inspect gastrointestinal and urogenital tract (Slatter, 2002). Local or expanded adhesions are of postoperative consequences of laparotomy (Menziez and Eliss, 1990). Many researchers have attempted to improve the techniques to minimize surgical trauma through reduction of postoperative adhesions and their consequences (Burns *et al.*, 1996; Ustun *et al.*, 1998; Treutner, 2000). Present surgical techniques modifications using appropriate approaches could reduce surgical trauma in abdominal cavity operations. Midline approach is the most commonly used approach in surgery of abdominal cavity in small animals (Slatter, 2002). The

reason is that surgical trauma and neuro-vascular structures involvement are minimum. It should be noted least involvement of mentioned structures that facilitate the operation are considered as inhibitory factors during healing processes postoperative days of the surgery and sometimes lead to wound dehiscence of the region. This may result in severe consequence of post-surgical adhesions of abdominal cavity is high and it is reported that the adhesions following appendectomy and pelvic limb surgery have been 47% and more than 91%, respectively (Ray *et al.*, 1993).

The current progress made in the analytical studies and in the field of biotechnology has led to a renewed interest in pharmacotherapy based on biogenic components. More attention has been given to apipharmacotherapy which utilizes the wound healing properties of active fractions of bee products. Honey has

been used in wound treatment as long ago as 2000 years (Forrest, 1982; Tovey, 2000). Hippocrates, used honey for this purpose. He used it for those wounds that healed difficultly (Brzezinski, 1995). In modern medicine, many physicians have demonstrated the remedial power of honey in treatment of different wounds, ulcers and burns (Subrahmanyam, 1998). Honey bears a broad spectrum antibacterial property without any deleterious effects on line tissue, despite other antiseptics (Molan, 1999). Physicochemical properties of honey such as Hygroscoy, high viscosity and low pH are of effective elements contributing its wound healing characteristics (Mathews and Binning, 2002). Honey contains carbohydrates, amino acids, minerals and vitamins that enhance both hydroxyproline synthesis and cellular proliferation in newly formed granulation tissue. It also contains hydrogen peroxide (H<sub>2</sub>O<sub>2</sub>) that induces fibroblast and hence leads to increased collagen contents and angiogenesis (Schmit *et al.*, 1992; Tur *et al.*, 1995). There are a large amount of glycine, methionine, arginin and prolin present in honey that take part in collagen formation and its storage (Gupta *et al.*, 1992). Since healing of linea alba is kind of wound healing process. The purpose of this study is assessment of wound healing effects of honey on linea alba following exploratory laparotomy and its inhibitory properties in postoperative intraperitoneal adhesions, wound dehiscence, hernia and visceral evisceration.

## MATERIALS AND METHODS

**Honey:** In this study, a natural, undiluted, unpasteurised honey was used. This honey was obtained from beehives in Targavar region of Urmia (West Azarbaijan province) and no additional procedures were performed. Each honey sample was first filtered with a sterile mesh to remove debris. Then they were irradiated at 25 KGy of Gamma ray for sterilization (Iranian Atomic Agency, Tehran, Iran) and stored at 2-8 C° until used. The average composition of the honey is given in Table 1.

**Animals:** This study was performed on 20 adult mongrel dogs with mean weight of 20±2.42 Kg. The animals were selected and divided into two equal groups randomly. Nutritional circumstances and their feeding conditions were the same before, during and after operations. Following overnight fasting, each animal was pre medicated with atropine (Darou pakhsh, Tehran, Iran) (0.04 mg kg<sup>-1</sup>, intramuscularly) and acepromazine maleate (Hoogsrraten, Belgium) (0.1 mg kg<sup>-1</sup>, intravenously) and then prepared for aseptic surgery in dorsal recumbency position. Then Ketamine hydrochloride (alfasan, Woerden, Holland) at 15 mg Kg<sup>-1</sup> was administered intramuscularly to achieve general anesthesia. Each animal was maintained on continuous

Table 1: Average composition of Targavar honey

Average (%)	Component
80.38	Reductant sugars
2.12	Sucrose
0.93	Fructose/Glucose
+	Diastase
-	Commercial glucose
0.05	Mineral components
17.08	Moisture
82.92	Concentration
12.5	Total acid
3.96	pH

intravenous drip of dextrose 5% through the operation period. Laparotomy was performed routinely on all animals through a caudal midline abdominal incision of 10 cm length (Fossum *et al.*, 2002). In treatment group, inner and outer surfaces of the incised edges of linea alba were treated with 10 mL honey and sutured with polyglactin 910 (Vicryl, Sherwood Daris and Geek, U.K) No.1 in simple continuous pattern. In control group, inner and outer surfaces of the incised edges of linea alba were only washed with 10 mL 0.9% NaCl sterile solution (Shahid Ghazi Co., Tabriz, Iran) and sutured as the same pattern and the same materials mentioned in the treatment group. The subcutaneous tissue and skin were sutured using chronic catgut No.1 (Supa Co., Tehran, Iran) in simple continuous and Nylon No.1 (Supa Co., Tehran, Iran) in simple interrupted patterns respectively. To manage the pain and discomfort Tramadol (KRKA, d. d., Novo mesto, Slovenia) (0.2 mg kg<sup>-1</sup>, IM) was administered every 3 h after surgery for 24 h and continued as needed.

**Assessment:** Three weeks following the operation, each animal was euthanized administrating intravenous injection of overdose of sodium thiopental (Biochemie GmbH, Vienna, Austria) (based on rules and the guidelines of the higher committee of veterinary clinical sciences of the institution) and autopsied. Adhesions were graded based on Evans's scoring system: 0 = No adhesion; 1 = spontaneously separating adhesion; 2 = adhesions separating by traction and 3 = adhesions separating by dissection (Evans *et al.*, 1993). Then specimens of linea alba were also taken on day 21 under general anesthesia and fixed in 10% neutral buffered formalin for subsequent histopathological studies. The Mann-Whitney U test was used to determine differences between treatment and control groups. A *P* value of less than 0.05 was considered statistically significant. (SigmaStat for Windows, version 2.03, Jandel Corporation, San Rafael, CA).

## RESULTS

There were no clinical signs of wound dehiscence, hernia and visceral evisceration in animals of both groups.

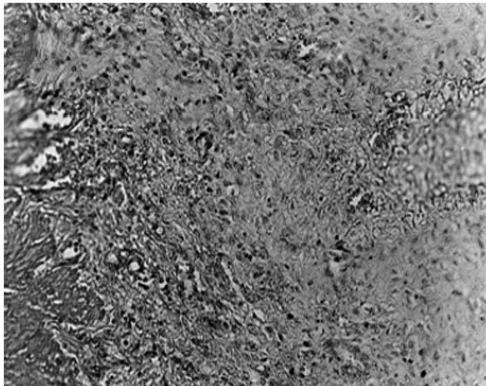


Fig. 1: Photomicrograph of the linea alba tissue section in treatment group (H and E,  $\times 100$ )

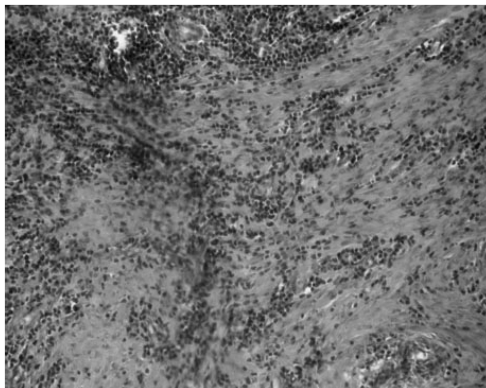


Fig. 2: Photomicrograph of the linea alba tissue section in control group (H and E,  $\times 100$ )

In treatment group six dogs (60%) were determined as grade 0 and two dogs (20%) as grade 1. Meanwhile one dog (10%) determined as grade 0 and three dogs (30%) were determined as grade 1 in control group.

Grade 2 and 3 adhesions were determined in one animal (10%) and one animal (10%) in treatment group while those of the control group were four animals (40%) and two animals (20%), respectively. The differences between two groups were significant ( $p < 0.05$ ). Histological analysis revealed that honey did not induce a specific inflammatory reaction and caused a fibrotic response compared with the untreated group (Fig. 1). Inflammatory reactions were seen as disseminated foci of inflammatory cells in control group (Fig. 2).

## DISCUSSION

This study was carried out to evaluate wound healing effects of honey on linea alba incision and its inhibitory influences on midline approach postoperative

consequences such as wound dehiscence, hernia and visceral evisceration. The reason was that linea alba incision is most commonly used approach in abdominal cavity operations (Fossum *et al.*, 2002).

This approach facilitates accessibility to viscera of abdominal cavity. Itself can act as an inhibitory factor during healing processes due to low vascularization of linea alba. This wound results in undesired postoperative consequences. To date many different models (Serosal abrasion, erosion of uterine horn, incision of ileum, anastomosis of large intestine) were used for stimulation of traumatic inflammation of peritoneal and serosal surfaces of abdominal cavity (Eric Mueller *et al.*, 2000; Boure *et al.*, 2002).

We believe the midline laparotomy shows more actual surgical trauma in comparison to other models. Many works have been conducted so far to induce healing processes and reduce post-surgical adhesions topically or systemically. Prophylactic antibiotic therapy, sodium citrate, heparin, prostigmin, antihistamine and corticosteroids have been used to achieve mentioned goals (Ellis, 1982; Sranelos and Le, 1996). Unfortunately no considerable achievements have been reported. Honey has been used as a remedy for wound healing for many centuries. In modern medicine, it has also been taken into consideration in recent years (Mathews and Binning, 2002; Subrahmany *et al.*, 2001; Osman *et al.*, 2003). Of the most important remedial properties of honey induction of healing process, high viscosity and osmolality, high acidity and containing inhibitory factors against microbial growth have been pointed out (Subrahmanyam *et al.*, 2001; Philips, 1993). In this study it has been demonstrated that severity and consistency of adhesions formed in control group are significantly much more than treatment group, in other words no or slight adhesions in four dogs (40%) of control group versus those in light dogs (80%) of treatment group and in contrast severe adhesions in six dogs (60%) of control group versus severe adhesions in two dogs (20%) of treatment group. These findings support the results of (Aysan *et al.*, 2002).

In histopathological findings no significant differences were seen between two groups regarding wound healing parameters despite macroscopic features that showed more success in treatment group. This study regardless complete determination of physicochemical mechanisms of honey demonstrated significant influence of honey in reduction of linea alba post-surgical adhesions and induction of wound healing processes of the region. Biomechanic evaluations can also be used to assess tension resistance of the postoperated linea alba in order to finalize benefits of the application of honey in midline laparotomy.

## REFERENCES

- Aysan, E., E. Ayar, A. Aren and C. Cifter, 2002. The role of intra-peritoneal honey administration in preventing post-operative peritoneal adhesions. *Euro. J. Obstet. Gyn.*, 104: 152-155.
- Boure, L.P., S.G. Pearce, C.L. Kerr, J.L. Lansdown, C.A. Martine, A.L. Hathway and J.L. Caswell, 2002. Evaluation of laparoscopic adhesiolysis for the treatment of experimentally induced adhesions in pony foals. *Am. J. Vet. Res.*, 63: 289-294.
- Brzezinski, T., 1995. *Historia medycyny*. PZWL, Warszawa, pp:141.
- Burns, J.W., K. Skinner, M.J. Colt, L. Burgess, R. Rose and M.P. Diamond, 1996. A hyaluronate based gel for the prevention of postsurgical adhesions: Evaluation in two animal species. *Fertil. Steril.*, 66: 814-820.
- Ellis, H., 1982. The causes and prevention of intestinal adhesions. *Br. J. Surg.*, 68: 241-243.
- Eric Mueller, P.O., W.P. Hay, B. Harmon and L. Amoroso, 2000. Evaluation of a bioresorbable hyaluronate-carboxymethylcellulose membrane for prevention of experimentally induced abdominal adhesions in horses. *Vet. Surg.*, 29: 48-53.
- Evans, D.M., K. Mc Aree and D.P. Guyton, 1993. Dose dependency and wound healing aspects of the use of tissue plasminogen activator in the prevention of intra-abdominal adhesions. *Am. J. Surg.*, 165: 229-232.
- Forrest, R.D., 1982. Development of wound therapy from dark ages to the present. *J. Roy. Soc. Med.*, 75: 268-273.
- Fossum, T.W., C.S. Hedlund, D.A. Hulse, A. Johanson, H.B. Seim, M.D. Willard and G. Carroll, 2002. *Text book of Small Animal Surgery*. (2nd Edn.), Mosby, London, pp: 165-173.
- Gupta, S.K., H. Singh, A.C. Varshney and P. Prakash, 1992. The therapeutic efficacy of honey in infected wounds in buffaloes. *Ind. J. Anim. Sci.*, 62: 521-523.
- Mathews, K.A. and A.G. Binning, 2002. Wound management using honey. *Comp. Cont. Edu. Pract. Vet.*, 24: 53-59.
- Menzies, D. and H. Ellis, 1990. Intestinal obstruction from adhesions. How big is the problem? *Ann. R. Coll. Surg. Engl.*, 72: 60-63.
- Molan, P.C., 1999. The role of honey in the management of wounds. *J. Wound Care*, 8: 415-418.
- Osman, O.F., L.S. Mansour and S. El-Hakin, 2003. Honey compound for wound care: A preliminary report. *Ann. burns fire disa.*, 16: 20-25.
- Philips, C.E., 1993. Honey for burns. *Glean. Bee Cult.*, 61: 284.
- Ray, N.F. and J.W. Larsen, 1988. Economic impact of hospitalization for lower abdominal adhesiolysis in the united states. *Surg. Gynecol. Obstet.*, 176: 271-276.
- Schmit, R.J., L.Y. Chung, A.M. Andrews and T.D. Turner, 1992. Hydrogen peroxide is a murine (L 929) fibroblast cell proliferation at micro-and nanomolar concentration. In: *Second European conference in advances in wound management*. Proc. Int. Conf. Center Harrogate.
- Slatter, D., 2002. *Textbook of Small Animal Surgery*, (3rd Edn.), Saunders, Philadelphia, pp: 405-413.
- Stravos, H.G. and T.C. Le, 1996. Physical barrier in adhesion prevention. *J. Reprod. Med.*, 41: 42-51.
- Subrahmanyam, M., A.G. Sahapur, N.S. Nagan, V.R. Bhagwat and J.V. Ganu 2001. Effect of topical application of honey on burn wound healing. *Ann. Burns Fire Disa.*, 16: 30-42.
- Subrahmanyam, M., 1998. A prospective randomized clinical and histological study of superficial burn wound healing with honey and silver sulfadiazine. *Burns*, 24: 157-161.
- Tovey, F., 2000. Honey and sugar as dressing for wounds and ulcers. *Trop. Doc.*, 30:1.
- Treutner, K.H. and V. Schumpelick, 2000. Adhesion prevention. Wish and reality. *Chirurg.*, 71: 510-517.
- Tur, E., L. Bolton and B.E. Constantine, 1995. Topical hydrogen peroxide treatment of ischemic ulcers in the guinea-pig: Blood recruitment in multiple skin site. *J. Am. Acad. Derm.*, 33: 217-221.
- Ustun, C., F.F. Yanik, I. Kocak, M.A. Canbaz and R. Cayli, 1998. Effects of Ringer's lactate, medroxyprogesterone acetate, gonadotropin-releasing hormone analogue and its diluents on the prevention of postsurgical adhesion formation in rat models. *Gynecol. Obstet. Invest.*, 46: 202-205.