

Clinical Assessment of Incisional Wound Healing Following Peritoneum-Sutured and Not-Sutured Techniques of Laparotomy in Omentopexed West African Dwarf (WAD) Goats

¹Ona Jonas Anayo, ¹Eze Athanasius Chinedu and ²Ukwueze Celestine Okwudili

¹*Department of Veterinary Surgery and Radiology, Faculty of Veterinary Medicine, University of Nigeria, Nsukka, Nigeria*

²*Department of Veterinary Surgery and Theriogenology, Michael Okpara University of Agriculture, Umudike, P.M.B. 7267 Umuahia, Abia State, Nigeria*

Key words: Laparotomy techniques, wound healing, clinical assessment, West African dwarf goat, sacrificed

Abstract: This study investigated the effects of peritoneum-sutured and not-sutured techniques in incisional wound healing in omentopexed WAD goats. Twenty male WAD goats aged 6-8 months used in this study were randomly assigned into four groups of 5 goats each. Left-flank-oblique-laparotomy, 6 cm long was performed in all the goats. In group I incision, only the muscle layers were sutured leaving the peritoneum unsutured. In group II, the muscle and the peritoneum were sutured together. In groups, III and IV, omentopexy was performed and the laparotomy incision sutured as in groups II and I, respectively. The goats were assessed for signs of pain, bleeding and exudation. One goat each per group was sacrificed on post-surgery days (psd); 3, 7, 14 and 42 to observe the peritoneal sites for hyperaemia, haemorrhage and tissue adhesions. The degree of tissue reaction was scored as mild, moderate or severe. Serosanguinous exudates were observed in goats in groups I and IV (psd 1-8) and II and III (psd 1-6), respectively. Hyperaemia was mild in groups I and II and moderate in groups III and IV. Group IV also had some areas of severe hyperaemia and haemorrhages observed following separation of adhered tissues. Peritoneum-omentum and muscle-omentum adhesions noted in group I resolved within psd 14. All the goats in groups III and IV displayed peritoneum-omentum adhesion. One goat in group III had rumen-peritoneum adhesion while peritoneum-omentum, peritoneum-rumen, muscle-rumen and muscle-omentum adhesions were observed in group IV. It was concluded that omentopexy creates adhesion with visceral complications that may delay wound healing in peritoneum-not sutured technique in male WAD goats.

Corresponding Author:

Ukwueze Celestine Okwudili

*Department of Veterinary Surgery and Theriogenology,
Michael Okpara University of Agriculture, Umudike,
P.M.B. 7267 Umuahia, Abia State, Nigeria*

Page No.: 12-18

Volume: 11, Issue 3, 2017

ISSN: 1815-9354

Research Journal of Agronomy

Copy Right: Medwell Publications

INTRODUCTION

The different tissue layers apposed following laparotomy incision depend on the choice of the surgeons (Kumar, 2002). Currently, there are contradicting reports on the best tissue apposition technique that facilitates wound healing following laparotomy. Moreso, it is noted that veterinarians depend on the healing properties of peritoneum for success of every abdominal surgery (Fubini and Ducharme, 2004). The complications that may arise following suturing and not-suturing of the peritoneum may include; bleeding, wound dehiscence, peritonitis, deleterious adhesion, excessive exudation, hyperaemia, haemorrhage and magnitude of post-operative pain. These complications result from the trauma to the mesothelial cells of the peritoneum, contact of the mesothelial cells with surgical instrument and suture materials. These complications may delay wound healing, reduce the stock value of the animals and add to the cost of animal production (Viana *et al.*, 2008).

While some literature in human and animals showed that surgical technique performed by Gynecologists and Obstetricians is by not suturing the peritoneum (Fubini and Ducharme, 2004), others argue that suturing of the peritoneum is the best technique (Kersjes *et al.*, 1985; Zarean and Zarean, 2006).

Omentopexy is a common surgical practice in large animals and small ruminants indicated for correction of left and right abomasal displacement (Aiello, 1998), abomasal volvulus and other visceral problems (Fubini and Ducharme, 2004). The success of this practice depends on incorporation of peritoneum in the omentopexy and inclusion of omental fold into the closure of the peritoneum and abdominal muscles. Omentopexy creates artificial adhesion of the omentum and abdominal muscles and this adhesion provides a live saving function through neovascularisation which serve as a wound healing process (Fox, 1970). Following blood clotting which is the first physiological response for self preservation, the clotting factors are squeezed to the injured site. Both the bleeders and the cut surrounding tissues bind together and this result in neovascularisation which facilitates wound healing. However, excess visceral adhesions can result in complication such as peritonitis, omental tear, ventral incisional hernia, pain and subsequently, delayed incisional wound healing. Since, the parietal peritoneum is liberally innervated by sharp pain nerve endings, it may be that inclusion of peritoneum in the suture line induces more pain than when it is not sutured (Omamegbe and Ukwani, 2010).

Hassan *et al.* (2002) noted that wound healing is one of the major reasons clients and patients seek for medical attention. The goal of wound management is to provide intervention that efficiently, progress wound through the

biologic sequence of repair and regeneration with minimal deformity (Aiello, 1998). This study was aimed to assess the rate of wound healing and the degree of complication associated with closure and non closure of peritoneum in omentopexy WAD goats.

MATERIALS AND METHODS

The university veterinary medical ethical committee approved this study. Twenty healthy male goats aged between 6 and 8 months were used for the study. The goats were randomly divided into four groups per a pen and kept at normal environmental temperature and natural light/darkness daily cycle. They were semi-intensively managed (tethered in the field for grazing on grasses (*Mucuna utilis*, *Pennisetum purpureum*) in the day and confined in the pen in the evening where their feed were supplemented with grasses and Bambara ground-nut (*Vigna subterrene* L. verda) waste. They were allowed to acclimatize for three weeks before the commencement of the experimental protocol.

Experimental protocols: The goats were randomly assigned into 4 experimental groups (I-IV) of 5 each. Left-Oblique-laparotomy, 6 cm long was performed in all the goats under xylazine (0.05 mg kg⁻¹) pre-anaesthetics given intramuscular and lignocaine hydrochloride (10 mg kg⁻¹) subcutaneous infiltration. In group I, muscle layers were sutured together leaving the peritoneum unsutured while in group II, the muscle layers and peritoneum were stitched together.

In groups III and IV, omentopexy was performed by anchoring double folds of the greater omentum sac at the transverse abdominal oblique muscle using size 2/0 nylon (Helmcare®, China) suture materials. In addition, tissue apposition was by closure of muscle and peritoneum layers together in group III, while muscle layers were sutured leaving the peritoneum unsutured in group IV. The muscle layers and peritoneum were sutured using size 2/0 chromic catgut (lifecare®, India) and in simple continuous suture pattern while skin was sutured using size 2/0 nylon (Helmcare®, China) and in horizontal mattress suture pattern.

Clinical assessment: The sutured sites were subjectively monitored on daily bases by visual observation for bleeding, exudation, wound dehiscence, incision hernia and signs of post-operative pain. One goat from each group was randomly selected on post-surgery days (psd); 3, 7, 14 and 42 and under anaesthesia, C-incision laparotomy was made 3 cm distal to the initial left-Oblique-laparotomy to exposed the incision site for gross examination of the incision sites for signs of hyperaemia, internal haemorrhage and tissue adhesions.

Assessment of pain was performed using the magnitude of response on each post-surgical days, behavioral response and verbal scale protocols as described by Carroll (2007) and Hensen (2003).

RESULTS AND DISCUSSION

Serosanguinous exudate was observed around the suture sites in all the experimental goats (Table 1). In groups, I and IV, the exudate was observed from psd 1-8 while in groups, II and III, it was observed from psd 1-6. Purulent exudate was observed between psd 3 and 4 in one goat in group IV.

Goats in groups, I and II exhibited signs of mild pain between psd 1 and 4 (Table 2). Those in groups, III and IV exhibited signs of moderate pain from psd 1 to 3 which later became mild between psd 4 and 7 (Table 2). Also groups III and IV showed signs of moderate mutilations (Table 3) while group IV exhibited more overt signs of moderate pains (Table 4).

The hyperaemia was mild in the sutured sites of groups I goats from psd 3-7 and moderate in the sutured sites of group II goats from psd 3-14. The sutured sites in group III goats were moderately hyperemic from psd 3-14. In group IV goats, the sutured sites were moderately hyperemic, severely hyperaemic and haemorrhagic on psd 3, 14 and 42, respectively (Table 5).

Table 1: Exudates from sutured sites among the experimental groups on Post-Surgery Days (PSD)

Groups	Types exudates	Number of animals	Severity	Post surgical days
I	Serosanguinous	5/5	++	1-8
II	Serosanguinous	5/5	+	1-6
III	Serosanguinous	5/5	+	1-6
IV	Serosanguinous	5/5	++	1-8
	Purulent	1/5	+	3-4

Scoring of exudates: - = no exudates, + = mild exudates, ++ = moderate exudates

Table 2: Post-surgical pain response of goats of experimental groups at different PSD

Groups	Post-surgery days			
	1	3	5	7
I	+	+	+	-
II	+	+	+	-
III	++	++	+	+
IV	++	++	+	+

Pain score: - = no pain. + = mild pain. ++ = moderate pain

Table 3: Post-surgical behavioral pain response of goats in different experimental groups

Behavioral pain response				
Group	Inappetence	Mutilation	Posture (abnormal)	Vocalization
I	+	+	-	+
II	+	+	-	+
III	+	++	+	+
IV	+	+++	+	+

Pain score: - = No response. + = mild response. ++ = moderate response

Adhesions of peritoneum to omentum and muscle to omentum around the suture sites were observed in two goats in group I on psd 3 and 7. No adhesion was observed in all the goats in group II throughout the period of the study. All the omentopexed goats had peritoneum to omentum adhesions on psd 3, 7, 14 and 42. One goat in group III showed peritoneum to rumen adhesion on psd 14 while two goats in group IV, one each on psd 14 and 42 showed muscle to rumen as well as peritoneum to rumen adhesion (Table 6 and Fig. 1).

Mild serosanguinous exudates observed in all the experimental groups (Table 1) within the first week in this study might be suggestive of early acute wound healing process. World Union of Wound Healing Society (2007) noted that serosanguinous wound exudates keeps wound sites in a moist state and aids migration of tissue replacing cells to the wound sites. In a study of closure verses non closure of peritoneum during cesarean section in man, it was observed that suturing peritoneum has less wound complication that facilitated earlier wound healing (Zarean and Zarean, 2006). This observation is also in line with the reports of Robin and Fiona (2005), Enoch and Price (2004) and Sunil *et al.* (1998) who noted that such fluid provides nutrients for cell metabolism and

Table 4: Post-surgical pain assessment (Verbal Ordinance 3-5 point scale)

Groups	Pain scores											
	No. pain			Mild pain			Moderate pain			Severe pain		
	1	2	3	1	2	3	1	2	3	1	2	3
I				+	+	-	-	-	-	-	-	-
II				+	+	-	-	-	-	-	-	-
III				+	+	+	+	+	-	-	-	-
IV				+	+	+	+	+	+	-	-	-

Pain scores: + = response. - = no response

Table 5: Hyperaemia at incision sites of goats of experimental groups on Post-Surgery Days (PSD)

Groups	PSD			
	3	7	14	42
I	+	+	-	-
II	+	+	+	-
III	++	++	++	-
IV	++	+++	+++	+**

Hyperaemia score: - = No hyperaemia., + = mild hyperaemia., ++ = moderate hyperaemia., +++ = severe hyperaemia., ** = haemorrhage

Table 6: Post-surgical tissue adhesions at sutured sites of different experimental groups

Adhesions				
Groups	Peritoneum/ Omentum	Muscle/ omentum	Peritoneum/ rumen	Muscle/ rumen
I	2/4	2/4	0/4	0/4
II	0/4	0/4	0/4	0/4
III	4/4	0/4	1/4	0/4
IV	4/4	2/4	2/4	2/4

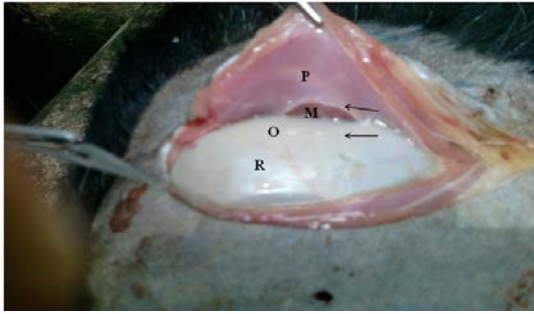


Fig. 1: The mediolateral section of the sutured site of the abdominal muscle: Shows the Muscle (M), Peritoneum (P) Rumen (R) and Omentum (O) of group I goats where the peritoneum was unsutured and without omentopexy

enables the diffusion of immune growth factors to the wound sites and subsequently facilitates the rate of wound healing.

It has been noted that prolonged exudation delays wound healing (World Union of Wound Healing Society, 2007). Judging by this therefore, it is pertinent that, the rate of wound healing was faster in groups I and II that have shorter duration of exudates (psd 1-6) compared to groups III and IV where tissue exudation stretched to psd 8. Fluid exudates from wounds are made up of phagocytic, immunogenic and other protein cells (World Union of Wound Healing Society, 2007). Therefore, excess exudation implies that these cells that facilitate wound healing might be lost, subsequently, healing will be delayed. The purulent exudates observed on psd 3 and 4 in group IV (Table 1) might equally be a sign of the wound complication. This finding is in line with the reports of Radostits *et al.* (1994) who submitted that excess exudation results in visceral friction that negatively affects wound healing.

It is possible that the non-sutured peritoneum groups I and IV became deficient of the immunogenic, phagocytic and other protein cell components of the peritoneum as suggested by Anderson *et al.* (1994). That probably accounted for the delayed wound healing indicated by prolonged and high fluid exudation (psd 1-8). Onah *et al.* (2014) reported wound healing by fibrosis following peritoneum not-sutured techniques of laparotomy sutures in West African Dwarf goat.

High fluid exudates might have accumulated in the dead space created as a result of non-sutured peritoneum (Fig. 1 and 4) and probably served as a medium for growth of microorganisms, hence, the purulent exudates noted in group IV. Although the scope of this work did not involve biogram, it might be argued that the observed purulent exudate was a phagocytic response to infection. Dwyer (2007) reported that purulent exudates are a

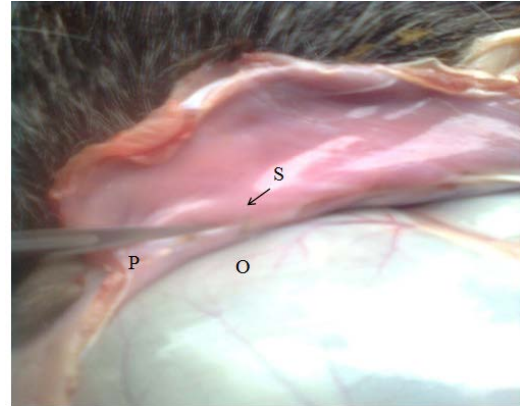


Fig. 2: The mediolateral section of the sutured site of the abdominal muscle: Shows the, Suture material (S), Peritoneum (P) and Omentum (O) of group II goats where the peritoneum was sutured and without omentopexy

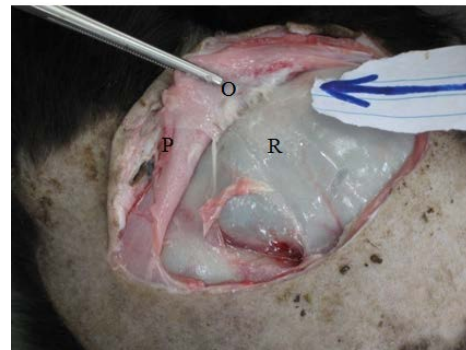


Fig. 3: The mediolateral section of the sutured site of the abdominal muscle: Shows the, Peritoneum (P), Rumen (R) and Omentum (O) of group III goats where the peritoneum was sutured and with omentopexy. Note the peritoneum- omentum adhesion (arrow)

combination of denatured protein, neutrophils and wound fluids. However, the duration of the purulence was short which showed that the immune system of the apparently healthy goats were able to curtail the likely infections.

These complications were not found in peritoneum sutured goats (groups II and III). This statement agrees with Kersjes *et al.* (1985) and Kumar (2002) who stated that peritoneum sutured alongside with muscles provide less complications. In a histopathology assessment of incisional wound behavior in West African Dwarf goat, Onah *et al.* (2014, 2015) observed that peritoneum sutured techniques facilitates wound healing. On the contrary, Fubini and Ducharme (2004) and Slatter and Dictrich (2003) stated that suturing peritoneum is deleterious to wound healing due to trauma caused to the sensitive tissue

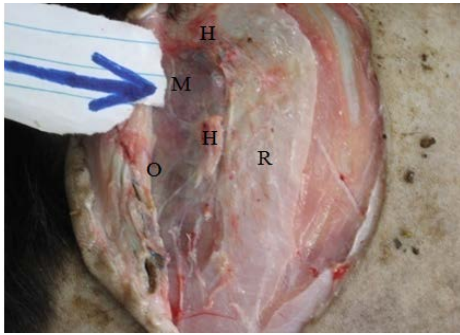


Fig. 4: The mediolateral section of the sutured site of the abdominal muscle: Shows the area of Haemorrhage (H), Muscle (M), Peritoneum (P), Rumen (R) and Omentum (O) of group IV goats where the peritoneum was not sutured and with omentopexy. Note the complex adhesions (arrow)

during manipulation (touching, pulling, contact with the surgical instrument) in the suturing process and injury caused by suture materials.

The pains observed in all the experimental groups (Table 3) was not surprising because it has been documented that any injury to the tissues of the body stimulates the nociceptive cells and subsequently results in pains (Omamegbe and Ukwani, 2010)

The moderate pain observed in groups III and IV as against mild pain in groups I and II (Table 3) might be as a result of the differentials in trauma additionally elicited on the pain nerve endings in the omentum following omentopexy. This is in accordance with the reports of Ebeid and Rings (1999) that pain may be a sign of omental stress caused by injury to the omentum. Prolongation of moderate pain in the omentopexed groups (III and IV) probably indicated that omental stretch involved the parietal peritoneum which has sharp pain transmitting sensations (Omamegbe and Ukwani, 2010).

Groups III and IV also showed signs of moderate and severe mutilations respectively (Table 3) with group IV showing in addition, more severe signs of moderate pains (Table 4). It is possible that wound complications from omental stretch and stress in unsutured peritoneum potentiated the severity of pains.

Acute wound healing are characterised by immediate neovascularisation of the injured site. Such vascular response might have resulted in the mild hyperaemia observed in groups I and II (Table 5). This is also in line with the reports of Bhuyan that vascular response to injury might be by increased in blood circulation and extravasation of blood components at the injured sites. It is possible that suture materials used for omentopexy traumatised the omental vessels which responded by

moderate increase in vascular circulation and subsequently moderate hyperaemia as observed in groups III and IV (Table 5). Such moderate hyperaemia might equally be indications of wound complications (World Union of Healing Society, 2007).

Further, the increase in blood circulation combined with unsutured peritoneum (group IV) might have resulted in severe hyperaemia and haemorrhage on psd 14 and 42, respectively (Fig. 2). This finding agrees with the report of Fubini and Ducharme (2004) who showed that omentopexy can cause incisional complication. Fox (1970) also noted that omentopexy may result in internal haemorrhage. However, Onah *et al.* (2014) observed that omentopexy performed in a peritoneum sutured technique of laparotomy has minimal blood and serum biochemical complication.

The adhesions observed in this study (Table 6) might be as a result of proximity of different tissue layers to one another and drainage of wound fluid surgically sequestered from incision sites and adjoining tissues. The peritoneum omentum adhesions observed in group I (Fig. 1) that resolved within 14 days might be as a result of injury to the peritoneum. Such adhesions resolved faster probably due to the wound healing role of the untraumatised omentum. This agrees with the reports of Fox (1970) that minor injury to the peritoneum resolves within few days and cause only transient fibrinous adhesions that has no significant effects on the animals. Also, Goldsmith (2004) in his study of the role of omentum stated that omentum prevents deleterious adhesions and facilitates wound healing. In addition, mild adhesion serves as a seal against break in continuity of viscera and provides neovascularisation of ischaemic tissues (Weibal and Majno, 1973; Fubini and Ducharme, 2004).

No adhesion was observed at the incision sites of goats in group II (Table 6, Fig. 2) which probably indicated that there was no complication at the incision sites. This agrees with the reports of Kersjes *et al.* (1985) and Kumar (2002) that suturing of peritoneum together with muscles reduces the risk of complications. Zarean and Zarean (2006) in his study of peritoneum suture and non-suture in man stated that suturing of peritoneum following abdominal incision causes less risk of peritoneal adhesions. On the contrary; Slatter and Dietrich (2003) and Fubini and Ducharme (2004) reported deleterious adhesions following suturing of peritoneum in dogs and cows, respectively.

The peritoneum-omentum adhesions found in all goats in groups III and IV (Table 6, Fig. 3) might have resulted from omentopexy performed in these groups using non-absorbable suture materials.

Omentopexy using non-absorbable suture materials artificially creates adhesions (Aiello, 1998). It has also been reported that non-absorbable suture materials create omental adhesions that last for a long period of time (Kersjes *et al.*, 1985).

The peritoneum-rumen adhesion found in group IV (Fig. 4) which led to haemorrhage during separation of the adhered tissues might be evidence of deleterious adhesions. It can be argued that such detrimental adhesions when combined with damage to the peritoneal tissues following unsutured peritoneum and omental stress can result in complications of abdominal pain, reduced visceral motility, internal haemorrhage and consequently prolong wound healing. Also the dead space created by unsutured peritoneum might have exposed this group IV to increased risk of sepsis and peritonitis, resulting in complicated peritoneum-rumen adhesions. Such observations above have been documented (Fox 1970; Aiello, 1998). Injury to the omentum following omentopexy can interfere with its immunogenic and angiogenic properties of omentum thereby reducing its wound healing potentials as reported by Goldsmith (2004).

CONCLUSION

It was concluded that in laparotomy procedures, peritoneum sutured technique facilitates wound healing while not-sutured technique delays wound healing.

REFERENCES

- Aiello, S.E., 1998. The Merck Veterinary Manual. 8th Edn., Merck and Co. Inc., New Jersey, ISBN: 09-911910-50-6, Pages: 2305.
- Anderson, D.E., D. Cornwell, G. St-Jean, A. Desrochers and L.S. Anderson, 1994. Comparison of peritoneal fluid analysis before and after exploratory celiotomy and omentopexy in cattle. *Am. J. Vet. Res.*, 55: 1633-1637.
- Ebeid, M. and D.M. Ring, 1999. Generalized peritonitis in cattle; 31 cases (1993-1997). *Bovine Pract.*, 3: 144-148.
- Enoch, S. and P. Price, 2004. Cellular, molecular and biochemical differences in the pathophysiology of healing between acute wounds, chronic wounds and wounds in the aged. *World Wide Wounds*, 13: 1-17.
- Fox, F.H., 1970. Esophagus, stomach, intestine and peritoneum: Bovine medicine and surgery. *Am. Vet. Publ.*, 1: 417-444.
- Fubini, S.L. and N.G. Ducharme, 2004. *Farm Animal Surgery*. Saunders, St. Louis, pp: 267-281.
- Goldsmith, H.S., 2004. The evolution of omentum transposition: From lymphedema to spinal cord, stroke and Alzheimer's disease. *Neurol. Res.*, 26: 586-593.
- Hansen, B.D., 2003. Assessment of pain in dogs: Veterinary clinical studies. *ILAR J.*, 44: 197-205.
- Hassan, A.Z., E.I. Amber, C.A. Awasum, B.D. Remi-Adewumi, A.S. Yila, F.B. Hassan and B.M. Jahun, 2002. A review of wound healing. *Niger. Vet. J.*, 23: 1-14.
- Kapur, M.L., A. Daneswar and P. Chopra, 1979. Evaluation of peritoneal closure at laparotomy. *Am. J. Surg.*, 137: 650-652.
- Kumar, A., 2002. Surgery of the Abdomen and Organs of the Digestive System. In: *Veterinary Surgical Techniques*, Kumar, A. (Ed.). Vikas Publishing House Pvt Ltd, Noida, India, pp: 264-315.
- Milewxyzk, M., 1989. Experimental studies on the development of peritoneal adhesions in cases of suturing and non-suturing of the parietal peritoneum in rabbits. *Ginekol Publ.*, 60: 1-6.
- Onamegbe, J.O. and Ukwani, 2010. Identification, diagnosis and management of pain in small animals-a review; *trop. Veterinary*, 28: 1-29.
- Onah, J.A., C.A. Eze, P.E. Aba and S.V. Shoyinka, 2015. Histopathology assessment of incisional wound-healing behaviour of peritoneum-sutured and not-sutured techniques following laparotomy and omentopexy in West African Dwarf (WAD) goats. *Comp. Clin. Pathol.*, 24: 317-322.
- Onah, J.A., C.A. Eze, P.E. Aba, C.O. Ukwueze and R. Ifeoma, 2014. Blood and serum biochemistry of omentopexed West African Dwarf (WAD) goats following peritoneum sutured and not sutured laparotomy. *Anim. Res. Int.*, 11: 1881-1888.
- Radostits, O.M., D.C. Blood and C.C. Gay, 1994. Diseases of the Alimentary Canal 1 and 11. In: *Veterinary Medicine; the Textbook of the Disease of Cattle, Sheep, Pig, Goats and Horses*, Radostits, O.M., D.C. Blood and C.C. Gay (Eds.). Bailliere Tindall Ltd, London, UK., pp: 157-312.
- Robin, R. and R. Fiona, 2005. Repair: Wound Healing and Regeneration. In: *Pathology Illustrated*, Robin, R. and R. Fiona (Eds.), Churchill Livingstone, London, pp: 99-117.
- Slatter, D.J. and U. Dietrich, 2003. Cornea and Sclera Textbook of Small Animal Surgery. 3rd Edn., Saunders, Philadelphia, USA., pp: 1379-1391.
- Sunil, R.L., A.D. Susan and J.F. Carolin, 1998. *Healing; Basic Pathology*. 2nd Edn., Arnold Publisher Limited, London, UK.,

- Viana, A.D.T., F.V. Daud, A. Bonizzia, P.H.F.D. Barros and E.S. Gouvea, 2008. Comparative study between parietal peritoneum suture and nonsuture in midline laparotomies in rats. *Acta Cirurgica Brasileira*, 23: 348-351.
- Weibel, M.A. and G. Majno, 1973. Peritoneal adhesion and their relation to abdominal surgery. *Am. J. Surg.*, 126: 345-353.
- Would Union of Healing Society, 2007. Wound exudates and the role dressing: Principle of best practice; a consensus document. London Mep Ltd, London, UK.
- Zarean, Z. and P. Zarean, 2006. Non-closure verses closure of peritoneum during caesarean section, a randomized study. *Eur. J. Obstr Gynecol Rep. Bio.*, 1: 126-267.